

# Facial nerve palsy, acute otitis media and Epstein-Barr virus infection

## Clinical Case

### Authors

**Diogo Cunha-Cabral**

Unidade Local de Saúde de Matosinhos – Hospital Pedro Hispano, Portugal

**André Alves Carção**

Unidade Local de Saúde de Matosinhos – Hospital Pedro Hispano, Portugal

**Pedro Marques Gomes**

Unidade Local de Saúde de Matosinhos – Hospital Pedro Hispano, Portugal

**Gustavo Lopes**

Unidade Local de Saúde de Matosinhos – Hospital Pedro Hispano, Portugal

**Delfim Duarte**

Unidade Local de Saúde de Matosinhos – Hospital Pedro Hispano, Portugal

**José Ferreira Penêda**

Unidade Local de Saúde de Matosinhos – Hospital Pedro Hispano, Portugal

**Correspondence:**

Diogo Cunha-Cabral  
diogo.cabral08@outlook.com | dcabral@med.up.pt

Article received on January 14, 2025.

Accepted for publication on March 19, 2025.

### Abstract

**Introduction:** Facial nerve palsy is a rare complication of acute otitis media. Despite most cases are assumed to have a bacterial origin, in a significant proportion of them there are no clinical or laboratorial signs indicative of bacterial infection. A viral etiology was proposed in some of these cases.

**Case summary:** In this work we present a case of facial nerve palsy secondary to acute otitis media caused by Epstein-Barr virus infection in a 3-year-old boy and review the previously published cases on this subject, focusing on clinical presentation, diagnosis, and treatment of this condition.

**Discussion:** Acute otitis media with facial nerve palsy can be a manifestation of Epstein-Barr virus primary infection. This etiology must be considered in all cases of facial nerve palsy secondary to acute otitis media, namely in those cases that lack signs of bacterial infection.

**Keywords:** Facial nerve palsy, Acute otitis media, Epstein-Barr virus, Infectious mononucleosis

### Introduction

Acute otitis media (AOM) is one of the most common infectious diseases in children, representing the principal cause of antibiotic prescription in the paediatric population <sup>1-3</sup>.

Although the incidence of AOM related complications has decreased in the last decades, they remain clinically significant <sup>4</sup>. Secondary facial nerve palsy (FNP) is one of the extracranial complications of AOM, affecting about 0,005% of patients with this condition <sup>5</sup>. The exact cause of FNP in AOM remains unclear. Several mechanisms have been proposed to explain this complication in patients with AOM assuming a bacterial origin <sup>5-7</sup>. However, in about 1/3 of these patients no bacteria can be isolated from the middle ear <sup>8</sup>. On the other hand, in some of sterile AOM, viruses

can be detected in the middle ear exudate or acute viral infection can be serologically diagnosed [9]. One of those viruses is Epstein-Barr virus (EBV), whose acute infection can cause neurologic complications in 0,5% to 7,5% of the patients<sup>10</sup>. In this work we present a case of FNP secondary to AOM caused by EBV infection in a child and review the few previously published case reports available in the literature on this subject.

## Material and Methods

We conducted a review of the literature in december 2024 using PubMed (Medline), Scopus and Web of Science databases. On the former, the following query was used: "facial nerve palsy" AND ("acute otitis media" OR "otitis media") AND ("Epstein-Barr virus" OR "EBV"). Similar terms were used in the two other databases.

Case reports and case series were retrieved, and we further searched their references for other relevant publications.

There were only included articles written in English or Portuguese. Publications lacking clinical data were excluded.

Informed consent was obtained from our patient legal representative for publication purposes.

## Case presentation

A 3-year-old previously healthy boy was admitted to the paediatric emergency department of a neighbour hospital because of a 12-hour history of facial asymmetry. He was on day two of oral antibiotic therapy with Amoxicillin + Clavulanic acid because of bilateral acute otitis media.

On admission he was afebrile and the remaining vital signs were normal. His general condition was good. He had a grade III right side peripheral facial palsy based on the House-Brackmann facial nerve grading system<sup>11</sup>. The remaining neurologic examination was normal. Otoscopy revealed bilateral erythematous and bulging tympanic membranes suggestive of bilateral AOM. There was no auricle protrusion or retroauricular inflammatory signs. The

laboratory tests revealed no leucocytosis and no other abnormalities apart from a slightly elevated C-reactive protein (CRP) (5,6 mg/L - normal value <3,0 mg/L).

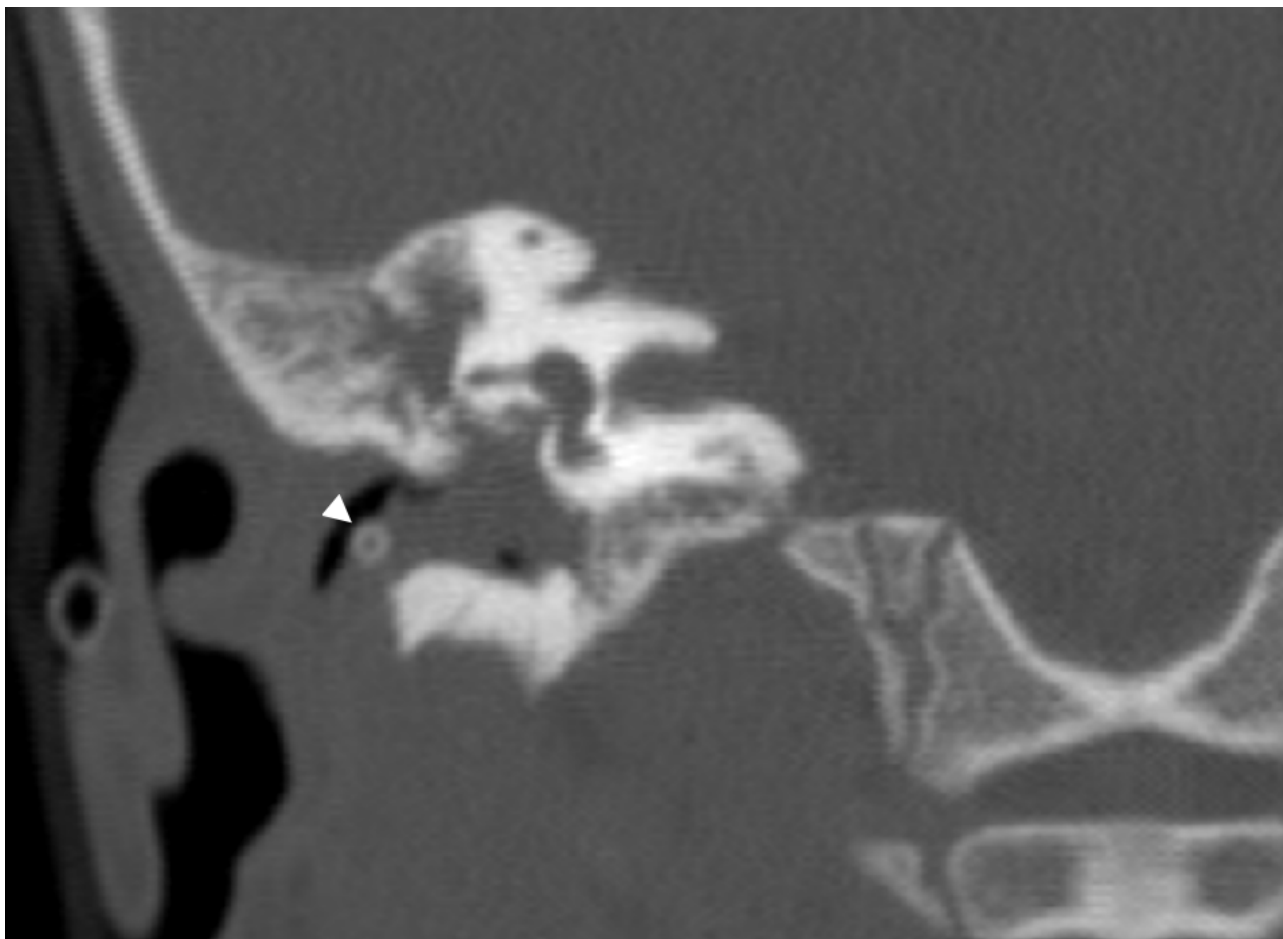
It was assumed the diagnosis of AOM-induced right side facial nerve palsy and he was immediately started on intravenous antibiotic therapy with ceftriaxone 60 mg/kg/day and clindamycin (90 mg/kg/day) as also on intravenous (IV) methylprednisolone (10 mg/day). In the same day he had bilateral myringotomy with placement of ventilation tubes (VT) (Shepard®). The middle ear was filled with purulent material which unfortunately was not sent for microbiology.

On the following day the patient was transferred to our hospital to complete antibiotic and corticoid therapy. He also initiated topical antibiotic therapy with Ofloxacin + Dexamethasone (1 mg/ml + 3 mg/ml) and started physical rehabilitation.

After 3 days of medical therapy, there was still no improvement of the facial nerve palsy. Otoscopy of the right ear revealed abundant purulent discharge and swelling of the posterior aspect of the external ear canal. Clinically, the patient was more irritable than usual and was refusing food, despite remaining afebrile. A contrasted head CT-scan revealed complete opacification of the right mastoid and middle ear with soft tissue density material that protruded through the tympanic membrane into the external ear canal displacing the ventilation tube (Figure 1). The ossicular chain was intact and there was no dehiscence of the tegmen tympani or of the tegmen mastoideum. The scutum was intact. The left tympanic membrane was thickened, and the ventilation tube was in the correct position. The ipsilateral middle ear and mastoid were aerated. The patient was then submitted to right ear canal wall-up mastoidectomy. The middle ear, mastoid antrum and mastoid cavity were filled with highly friable, polypoid material which was carefully removed and sent for histology and microbiology. The ossicular chain and chorda tympani were preserved. The mastoidectomy

**Figure 1**

CT-scan of the right ear showing complete obliteration of the middle ear with soft tissue density material that protruded through the tympanic membrane into the external ear canal displacing the ventilation tube (arrowhead).



cavity and middle ear were filled with Spongostan® and irrigated with ofloxacin. Samples of otorrhea collected in the beginning of surgery were sent for microbiology too.

Serologic tests were also performed. Positive antiviral capsid antigen (VCA) IgM and negative anti-VCA IgG serologies suggested a primary EBV infection. Therefore, we searched for Epstein-Barr virus-encoded small RNAs (EBERs) in the biopsied material.

The ear discharge was sterile. The histopathologic analysis of the biopsied material revealed an inflammatory infiltrate, and it was detected expression of EBER by in situ hybridization analysis.

We assumed the diagnosis of facial nerve palsy secondary to AOM caused by an acute EBV infection.

After 8 days of IV antibiotic therapy and weaning of corticoid therapy the patient was discharged home. He continued topic therapy with Ofloxacin + Dexamethasone (1 mg/ml + 3 mg/ml) for two more weeks.

Three months after the initial presentation, the facial palsy had completely resolved, and he had a normal otoscopy.

## Results

After reviewing of the available literature, we selected a total of 6 articles. Only 5 publications were included in this review, after exclusion of one case report because it was written in German. Among the included ones, 2 were single case reports and 3 were small case series. Table 1 summarizes the studies included in this work.

**Table 1**  
Summary of the case reports included in this work

ID	Author (date)	Age	Sex	Presentation	Laboratory tests	Middle ear cultures	EBV infection diagnosis	Medical Therapy (duration)	VT Placement	Mastoideotomy	Outcome
1	Michel Pope et al. 1975	15 years old	Male	Clinical presentation: -Otalgia and fever Physical examination: -Right side facial paresis (HB – NA) -Cervical lymphadenopathy	Leucocytosis with 50% atypical lymphocytes	NA	Positive monospot test	NA	No	Yes (Granulation tissue filling the mastoid and the middle ear)	Complete Recovery (6 weeks)
2	Eeten Faber et al. 2017	7 Month old	Male	Clinical presentation: -Otalgia and fever Physical examination: -Left side facial paresis (HB – grade IV) -Cervical lymphadenopathy Hepatosplenomegaly	NA	NA	Positive EBV-DNA PCR (peripheral blood) Positive EBV* (granulation tissue from mastoid)	Oral Azithromycin (2 days) IV ceftriaxone + Topic eardrops (Hydrocortisone, colistin and bacitracin) (9 days)	Yes	Yes	Complete Recovery (6 weeks)
3		32 month old	Male	Clinical presentation: -Otitis media with effusion, fever and facial asymmetry Physical examination: -Thickened mucosa without signs of acute otitis media -Left side facial paresis (HB – grade V)	NA	NA	Positive EBV-DNA PCR (peripheral blood)	Oral amoxicillin/ clavulanic acid (5 days) IV ceftriaxone + Topic eardrops (Hydrocortisone, colistin and bacitracin) (5 days)	Yes	Yes + facial nerve decompression (6 weeks after initial presentation)	Grade II Facial paresis (6-months follow-up)
4	Vogeltnik and Matos 2017	26 month old	Male	Clinical presentation: -Left otalgia and facial asymmetry Physical examination: -Dull, opaque and bulging tympanic membrane -Left side facial paresis (HB – grade NA)	Normal	Negative	Positive anti-VCA IgM and IgG ISH-EBER	IV amoxicillin-clavulanate (NA)	Yes	Yes (Polypoid tissue filling the mastoid antrum and the middle ear)	Complete Recovery (time – NA)
5		27 month old	Female	Clinical presentation: -Left otalgia and facial asymmetry Physical examination: -Dull, opaque and bulging tympanic membrane -Left side facial paresis (HB – grade NA)	Normal	Positive (Staphylococcus lugdunensis)	Positive anti-VCA IgM	IV amoxicillin-clavulanate (NA)	Yes	No	Complete Recovery (time – NA)
6		17 month old	Female	Clinical presentation: -Facial asymmetry Physical examination: -Dull, opaque and bulging tympanic membrane -Right side facial paresis (HB – grade NA)	Normal	Negative	Positive anti-VCA IgM and IgG	IV amoxicillin-clavulanate (NA)	Yes	No	Residual facial paresis (2-year follow-up)
7		26 month old	Male	Clinical presentation: -Right otalgia and facial asymmetry Physical examination: -Dull, opaque and bulging tympanic membrane -Right side facial paresis (HB – grade NA)	Elevated CRP	Negative	Positive anti-VCA IgM and IgG	IV amoxicillin-clavulanate (NA)	Yes	No	Complete Recovery (time – NA)
8		25 month old	Female	Clinical presentation: -Left otalgia, otorrhea, fever and facial asymmetry Physical examination: -Dull, opaque and bulging tympanic membrane -Left side facial paresis (HB – grade NA)	Normal	Negative	Positive anti-VCA IgM	IV amoxicillin-clavulanate (NA)	Yes	No	Complete Recovery (time – NA)
9		18 month old	Female	Clinical presentation: -Otitis media with effusion, fever and facial asymmetry Physical examination: -Bilateral redness and bulging of the tympanic membrane -Right side facial paresis (HB – grade V) -Cervical lymphadenopathy	Leukocytosis with 7% atypical lymphocytes	NA	Positive anti-VCA IgM and IgG Positive EBV-DNA PCR (peripheral blood)	Prednisolone (9 days)+ Vitamin B12 (12 weeks)	No	No	Complete Recovery (12 weeks)
10	Yamaguchi, Suzuki et al. 2021	19 month old	Female	Clinical presentation: -Respiratory tract symptoms, fever and facial asymmetry Physical examination: -Bilateral acute otitis media -Left side facial paresis (HB – grade NA) -Cervical lymphadenopathy	Leukocytosis with 4% atypical lymphocytes	NA	Positive anti-VCA IgM and IgG Positive EBV-DNA PCR (peripheral blood)	Prednisolone (9 days)+ Vitamin B12 (7 weeks)	No	No	Complete Recovery (6 weeks)
11	Castellazzi, Torretta et al. 2023	18 month old	Male	Clinical presentation: -Bilateral acute otitis media and fever Physical examination: -Bilateral tympanic membrane hyperemia and middle ear effusion -Left side facial paresis (HB – grade IV)	Leucocytosis with neutrophilia Elevated CRP	Negative	Positive anti-VCA IgM	IV cefotaxime + IV acyclovir + Oral Betamethasone (15 days)	Yes	No	Complete Recovery (3 months)

CRP – C reactive protein; EBERs: Epstein-Barr virus-encoded small RNAs. EBV - Epstein-Barr virus; HB – House Brackman facial nerve grading system; ISH - In-situ hybridization; NA - not available; PCR - Polymerase Chain Reaction; VCA - Antiviral capsid antigen; VT – ventilation tube. \* The method that was used was not mentioned

## Discussion

### 1. Presentation

Despite being rare, facial nerve palsy is the most common cranial nerve pathology both in children and adults<sup>12</sup>. The causes of facial nerve palsy can be divided between acquired and congenital. Among the acquired etiologies, idiopathic facial palsy (Bell's palsy) is the most common<sup>12,13</sup>. However, acquired dysfunction of the facial nerve may be secondary to trauma, neoplasms, and infections<sup>12</sup>.

Although the widespread of antibiotic treatment of AOM decreased the incidence of complications, AOM remains the main infectious cause of peripheral facial palsy in children<sup>13-15</sup>. When facial nerve palsy occurs in the context of an acute otitis media, it is usually assumed that it is secondary to bacterial infection. However, some of these cases not only fail to demonstrate clinical and laboratorial signs suggestive of a bacterial infection but also end up by having negative cultures from the middle ear<sup>9,16</sup>. Besides that, in up to 1/3 of these cases, patients have viruses detected in the middle ear or have serologically confirmed viral infections<sup>9</sup>. This suggests that some viruses, such as EBV, might be involved in the pathogenesis of AOM related facial nerve palsy<sup>8</sup>.

EBV is a ubiquitous herpes family virus that is mainly transmitted through respiratory secretions during childhood<sup>17,18</sup>. Primary EBV infection presentation is diverse and depends on the age and immune status of the patient. In most cases it is asymptomatic or presents as a benign febrile viral upper respiratory infection. In older patients, namely in adolescents and young adults, primary infection typically presents as infectious mononucleosis (IM) (fever, pharyngitis, adenopathy, hepatosplenomegaly, and fatigue)<sup>18,19</sup>. Acute infection may also be associated with neurologic complications in a small percentage of cases<sup>19,20</sup>.

None of the 11 cases included in this work occurred in adults. The case reported by Michel et al., was of a 15-year-old adolescent whose presentation was infectious

mononucleosis accompanied by peripheral facial palsy and acute otitis media<sup>21</sup>. The median age of presentation of the patients of the remaining cases was of 22 months (minimum 7 and maximum 32 months). Our patient was 38 months old at the time of the initial presentation. In addition to facial asymmetry, most of those patients reported otalgia and fever. Besides otoscopic signs suggestive of AOM, 4 patients also had cervical lymphadenopathy and one had hepatosplenomegaly. All the patients whose facial palsy was graded according to House-Brackman scale had a grade superior to III. None of the patients had complete facial palsy (grade VI). Our patient had a grade III right side facial palsy.

### 2. Laboratorial findings

One of the typical laboratory findings of IM is the transient appearance of atypical lymphocytes<sup>22</sup>. In fact, lymphocytosis and the presence of  $\geq 10\%$  of atypical lymphocytes are two of the Hoagland's criteria for the diagnosis of IM<sup>23</sup>. Nevertheless, despite their high specificity, the lack of sensitivity does not permit acute EBV-infection exclusion when they are not present. Elevated CRP is frequent in the acute EBV-infection<sup>24</sup>. Also, elevated levels of alanine aminotransferase (ALT), Aspartate Aminotransferase (AST) and lactate dehydrogenase (LDH) are commonly found in older patients. These findings are less frequently found in preschool children<sup>24</sup>.

Only 3 of the patients had leukocytosis with the presence of atypical lymphocytes. In one case, the patient had leukocytosis with neutrophilia. Elevated CRP was present in 3 patients. 4 patients had normal blood cell counts and CRP. Our patient had leukocytosis with mildly elevated CRP. In none of the reported cases were mentioned liver enzyme levels.

Acute EBV infection gives rise to an immune response which generates specific and non-specific (heterophile) antibodies in the host. These heterophile antibodies (HA) are able to agglutinate animal erythrocytes, a characteristic that is behind Paul-Bunnell

and Monospot tests<sup>22</sup>. Although these tests have high specificity, they are less sensitive than EBV-specific serologies<sup>25</sup>. In fact, HA antibodies can be falsely negative in about 25% of patients within the first week and 6.5% of patients in the second week of IM<sup>26</sup>. On the other hand, they can remain positive for as long as 1 year after the infection, requiring adequate clinical interpretation<sup>25</sup>. Specific EBV antibodies are directed against viral proteins produced in different phases of the infection<sup>22</sup>. VCA IgM antibodies are usually present 8 days before the onset of symptoms and last for 4 to 8 weeks. VCA IgG antibodies appear later in the infection, but in some cases can be detected when the symptoms appear, persisting indefinitely<sup>25</sup>. Thereby, acute EBV infection can be serologically detected by isolated positive anti-VCA IgM antibodies or positive anti-VCA IgM and IgG antibodies<sup>22,25</sup>. Anti-EBV nuclear antigen (EBNA) IgG antibodies are only detected 2 months after the symptoms, and indicates past EBV infection<sup>25</sup>. It is important to mention that in about 9% of patients with IM, specific EBV serologies are negative. Therefore, in patients in whom acute EBV infection is highly suspected these serologies should be repeated<sup>25</sup>.

EBV DNA can also be detected and quantified by Polymerase Chain Reaction (PCR) in peripheral blood samples. However, in the clinical setting of an acute EBV infection its role may be limited as a low number of EBV DNA copies may not be useful to distinguish between an acute infection and the presence of latently infected cells [25]. EBV can also be identified in tissue samples by detecting EBV-encoded small RNA (EBER) positive cells by in-situ hybridization (ISH)<sup>27</sup>.

In 8 of the 11 reported cases, specific EBV serologies were used to make the diagnosis of acute EBV infection. In 2 of these patients, EBV DNA was also detected by PCR in the peripheral blood. In one of the cases reported by Vogelnik and colleagues, EBER positive cells were identified using ISH in tissue samples from the material filling the mastoid antrum and the middle ear<sup>8</sup>. In our patient, the

diagnosis of EBV primary infection was made both with the serologies and the detection of EBER in samples of the granulation tissue from the middle ear and the mastoid.

### 3. Treatment

Most cases of AOM related complications are effectively treated with correct antibiotic therapy with or without ventilation tube placement. In case of AOM related facial nerve palsy, myringotomy with or without VT placement is usually recommended when the tympanic membrane is intact<sup>6</sup>. Besides the therapeutic utility, this procedure also allows collection of samples of middle ear exudates for microbiological analysis. Corticosteroid use in facial palsy may help reducing time of recovery by reducing the facial nerve inflammation and edema<sup>6,28,29</sup>. The role of antivirals in the treatment of facial palsy without AOM is uncertain<sup>30</sup>. Even in the cases of acute EBV infection there was no demonstrable benefit in the use of acyclovir<sup>31</sup>. Upon the diagnosis of peripheral facial palsy associated to AOM most patients of the reviewed cases started immediately IV antibiotic treatment. The cases reported by Eaton et al. were given oral antibiotic treatment initially, but switched to IV after few days. Those patients also started topic eardrops of antibiotic and corticosteroid<sup>28</sup>. One patient also started IV acyclovir and oral betamethasone treatment<sup>6</sup>. Only the cases reported by Yamaguchi and colleagues did not receive any antibiotic treatment. Instead, those patients started oral prednisolone and Vitamin B12<sup>29</sup>. Among the 11 reviewed cases, only three patients did not have VT placed. Our patient was given IV ceftriaxone and clindamycin and IV methylprednisolone. He also started topic eardrops containing antibiotic and corticosteroids after VT placement.

In the setting of facial nerve palsy secondary to AOM, mastoidectomy is usually reserved for patients who experiment clinical worsening or that fail to improve after 7 days of adequate antibiotic treatment. In these cases, temporal



bone CT scan is usually performed to search for signs of coalescent mastoiditis indicating the need for surgery <sup>32,33</sup>. Surgical decompression of the facial nerve is not recommended in an early stage because the inflammation of the nerve increases the risk of damaging it <sup>33</sup>. This procedure is usually reserved for patients with complete facial nerve palsy who have > 95% degeneration documented on Electroneuronography (between the 4<sup>th</sup> and the 14<sup>th</sup> days after the initial presentation) <sup>34</sup>. Only 4 of the reviewed cases were subjected to mastoidectomy. The rationale behind the decision to perform mastoidectomy in the case one reported by Vogelnik and colleagues was not revealed <sup>8</sup>. In the cases reported by Eeten et al. one had mastoidectomy 6 days after the initial presentation after no demonstrable improvement with the antibiotic treatment and the other had mastoidectomy and facial nerve canal decompression after no improvement of the facial nerve palsy after 6 weeks <sup>28</sup>. Our patient had mastoidectomy on day 4 of presentation after no improvement of the facial asymmetry and worsening of the general condition and of the otoscopy findings.

#### 4. Prognosis

In all but one of the reported cases there was a complete recovery of the facial nerve palsy. The patient that did not have complete recovery still had a significant improvement. Our patient also had a complete recovery. The good outcomes of the cases reported in this work are in accordance with the previously described favorable prognosis of facial nerve palsy secondary to AOM <sup>6,28</sup>. As previously mentioned, the therapeutic strategies reported in the reviewed cases were significantly different from each other's. This applies not only to the pharmacological treatment, but also to the surgical treatment. Despite that, all the patients had full or significant recovery. This makes it more difficult to draw conclusions about the treatment of this condition. Even in the patients who had mastoidectomy there is no evidence that the

palsy was not going to resolve if surgery had not been performed.

## Conclusion

The authors of this work suggest considering EBV primary infection in all cases of facial nerve palsy secondary to AOM, mainly in those cases who fail to demonstrate typical findings of bacterial infection. All these patients should be started on IV antibiotics and corticosteroids immediately and have myringotomy with VT placement and middle ear cultures. EBV specific serologies should also be performed in all patients. Mastoidectomy can be considered in some patients who fail to improve or experience worsening of the symptoms, however, there is no clear indication that it causes a significant change in the prognosis.

#### List of abbreviations:

ALT: Alanine aminotransferase  
AOM: Acute otitis media  
AST: Aspartate Aminotransferase  
CRP: C Reactive Protein  
EBERs: Epstein-Barr virus-encoded small RNAs  
EBNA: Anti-EBV nuclear antigen  
EBV: Epstein-Barr virus  
FNP: Facial nerve palsy  
HA: Heterophile antibodies  
IM: Infectious mononucleosis  
ISH: In-situ hybridization  
IV: Intravenous  
LDH: Lactate dehydrogenase  
PCR: Polymerase Chain Reaction  
VCA: Antiviral capsid antigen  
VT: ventilation tube

#### Conflict of Interests

The authors declare that they have no conflict of interest regarding this article.

#### Data Confidentiality

The authors declare that they followed the protocols of their work in publishing patient data.

## Human and animal protection

The authors declare that the procedures followed are in accordance with the regulations established by the directors of the Commission for Clinical Research and Ethics and in accordance with the Declaration of Helsinki of the World Medical Association.

## Privacy policy, informed consent and Ethics committee authorization

The authors declare that they have obtained signed consent from the participants and that they have local ethical approval to carry out this work.

## Financial support

This work did not receive any grant contribution, funding or scholarship.

## Scientific data availability

There are no publicly available datasets related to this work.

## References

1. Teele DW, Klein JO, Rosner B. Epidemiology of otitis media during the first seven years of life in children in greater Boston: a prospective, cohort study. *J Infect Dis*. 1989 Jul;160(1):83-94. doi: 10.1093/infdis/160.1.83.
2. Casselbrant ML, Mandel EM. Epidemiology. In: Rosenfeld RM, Bluestone CD. Eds. *Evidence-Based Otitis Media*, 2nd Ed. Oxford: Elsevier, 2003. p. 147-162
3. Gates GA. Acute otitis media and otitis media with effusion. *Otolaryngology, Head and Neck Surgery* 3rd ed St Louis: Mosby. 1998.
4. Lesperance MM. Cummings Pediatric Otolaryngology. Elsevier Health Sciences; 2021.
5. Teixeira DN, de Figueiredo MV, Fernandes RG, Muranaka, Lobo JAA, de Sales Chagas JF. et al. Peripheral facial paralysis as a consequence of acute otitis media: physiopathology, associated factors and treatment. *Otorhinolaryngol Head Neck Surg*, 2020; doi: 10.15761/OHNS.1000225
6. Castellazzi ML, Torretta S, Pietro GMD, Ciabatta A, Capaccio P, Caschera L. et al. Acute otitis media-related facial nerve palsy in a child: a case report and a literary review. *Ital J Pediatr*. 2023 Jan 14;49(1):8. doi: 10.1186/s13052-022-01405-4.
7. Jacobsson M, Nylen O, Tjellström A. Acute otitis media and facial palsy in children. *Acta Paediatr Scand*. 1990 Jan;79(1):118-20. doi: 10.1111/j.1651-2227.1990.tb11344.x.
8. Vogeltnik K, Matos A. Facial nerve palsy secondary to Epstein-Barr virus infection of the middle ear in pediatric population may be more common than we think. *Wien Klin Wochenschr*. 2017 Nov;129(21-22):844-847. doi: 10.1007/s00508-017-1259-y
9. Hyden D, Akerlind B, Peebo M. Inner ear and facial nerve complications of acute otitis media with focus on bacteriology and virology. *Acta Otolaryngol*. 2006 May;126(5):460-6. doi: 10.1080/00016480500401043.
10. Portegies P, Corssmit N. Epstein-Barr virus and the nervous system. *Curr Opin Neurol*. 2000 Jun;13(3):301-4. doi: 10.1097/00019052-200006000-00012.
11. House JW, Brackmann DE. Facial nerve grading system. *Otolaryngol Head Neck Surg*. 1985 Apr;93(2):146-7. doi: 10.1177/019459988509300202.
12. Wang CS, Sakai M, Khurram A, Lee K. Facial nerve palsy in children: a case series and literature review. *Otolaryngology Case Reports*. 2021;20:100297. doi: 10.1016/j.xocr.2021.100297
13. Hanci F, Türay S, Bayraktar Z, Kabakuş N. Childhood facial palsy: etiologic factors and clinical findings, an observational retrospective study. *J Child Neurol*. 2019 Dec;34(14):907-912. doi: 10.1177/0883073819865682
14. Evans AK, Licameli G, Brietzke S, Whittemore K, Kenna M. Pediatric facial nerve paralysis: patients, management and outcomes. *Int J Pediatr Otorhinolaryngol*. 2005 Nov;69(11):1521-8. doi: 10.1016/j.ijporl.2005.04.025.
15. Psillas G, Antoniadis E, Ieridou F, Constantinidis J. Facial nerve palsy in children: a retrospective study of 124 cases. *J Paediatr Child Health*. 2019 Mar;55(3):299-304. doi: 10.1111/jpc.14190.
16. Heikkinen T. Role of viruses in the pathogenesis of acute otitis media. *Pediatr Infect Dis J*. 2000 May;19(5 Suppl):S17-22; discussion S22-3. doi: 10.1097/00006454-200005001-00004.
17. Nowalk A, Green M. Epstein-Barr Virus. *Microbiol Spectr*. 2016 Jun;4(3). doi: 10.1128/microbiolspec.DMIH2-0011-2015.
18. Nowalk A, Green M. Epstein-Barr Virus. *Microbiol Spectr*. 2016 Jun;4(3). doi: 10.1128/microbiolspec.DMIH2-0011-2015.
19. Cohen JI. Epstein-Barr virus infection. *N Engl J Med*. 2000 Aug 17;343(7):481-92. doi: 10.1056/NEJM200008173430707.
20. Häusler M, Ramaekers VT, Doenges M, Schweizer K, Ritter K, Schaade L. Neurological complications of acute and persistent Epstein-Barr virus infection in paediatric patients. *J Med Virol*. 2002 Oct;68(2):253-63. doi: 10.1002/jmv.10201.
21. Michel RG, Pope TH Jr, Patterson CN. Infectious mononucleosis, mastoiditis, and facial paralysis. *Arch Otolaryngol*. 1975 Aug;101(8):486-9. doi: 10.1001/archotol.1975.00780370028010.
22. Naughton P, Healy M, Enright F, Lucey B. Infectious Mononucleosis: diagnosis and clinical interpretation. *Br J Biomed Sci*. 2021 Jul;78(3):107-116. doi: 10.1080/09674845.2021.1903683.
23. Hoagland RJ. Infectious mononucleosis. *Prim Care*. 1975 Jun;2(2):295-307.
24. Topp SK, Rosenfeldt V, Vestergaard H, Christiansen CB, Von Linstow ML. Clinical characteristics and laboratory findings in Danish children hospitalized with primary Epstein-Barr virus infection. *Infect Dis (Lond)*. 2015;47(12):908-14. doi: 10.3109/23744235.2015.1082036.
25. Tan JW, Hu J-R. Fever with atypical lymphocytosis: pearls and pitfalls in Epstein-Barr virus serology. *BMJ Case Rep*. 2023 May 3;16(5):e250081. doi: 10.1136/bcr-2022-250081.
26. Womack J, Jimenez M. Common questions about infectious mononucleosis. *Am Fam Physician*. 2015 Mar 15;91(6):372-6.



27. Papan C, Kremp L, Weiß C, Petzold A, Schroten H, Tenenbaum T. Infectious causes of peripheral facial nerve palsy in children-a retrospective cohort study with long-term follow-up. *Eur J Clin Microbiol Infect Dis*. 2019 Nov;38(11):2177-2184. doi: 10.1007/s10096-019-03660-6.
28. Eeten EV, Faber H, Kunst D. Surgical treatment for Epstein-Barr virus otomastoiditis complicated by facial nerve paralysis: a case report of two young brothers and review of literature. *J Int Adv Otol*. 2017 Apr;13(1):143-146. doi: 10.5152/iao.2017.2788.
29. Yamaguchi M, Suzuki M, Morita M, Hasegawa S, Ito Y. Facial nerve palsy with acute otitis media associated with EB virus infection. *Pediatr Int*. 2021 May;63(5):599-600. doi: 10.1111/ped.14451
30. Turgeon RD, Wilby KJ, Ensom MH. Antiviral treatment of Bell's palsy based on baseline severity: a systematic review and meta-analysis. *Am J Med*. 2015 Jun;128(6):617-28. doi: 10.1016/j.amjmed.2014.11.033.
31. Tambini DT, Roberto. Acyclovir for treatment of infectious mononucleosis: a meta-analysis. *Scand J Infect Dis*. 1999;31(6):543-7. doi: 10.1080/00365549950164409.
32. Gaio E, Marioni G, de Filippis C, Tregnaghi A, Caltran S, Staffieri A. Facial nerve paralysis secondary to acute otitis media in infants and children. *J Paediatr Child Health*. 2004 Aug;40(8):483-6. doi: 10.1111/j.1440-1754.2004.00436.x.
33. Joseph EM, Sperling NM. Facial nerve paralysis in acute otitis media: cause and management revisited. *Otolaryngol Head Neck Surg*. 1998 May;118(5):694-6. doi: 10.1177/019459989811800525.
34. Chang C, Cass SP. Management of facial nerve injury due to temporal bone trauma. *Am J Otol*. 1999 Jan;20(1):96-114.